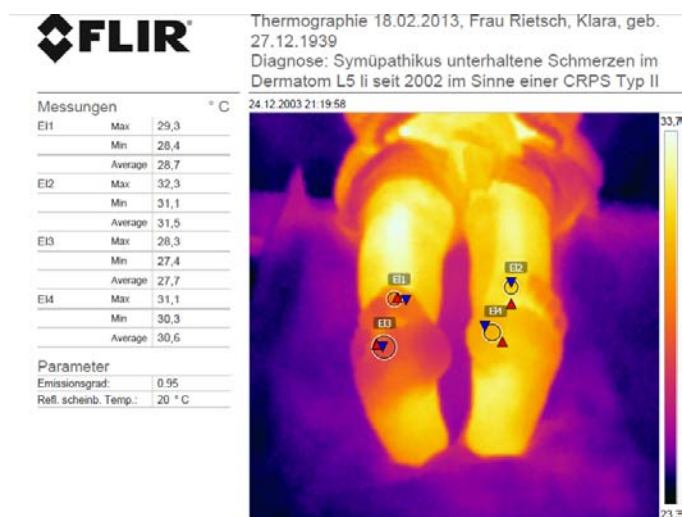
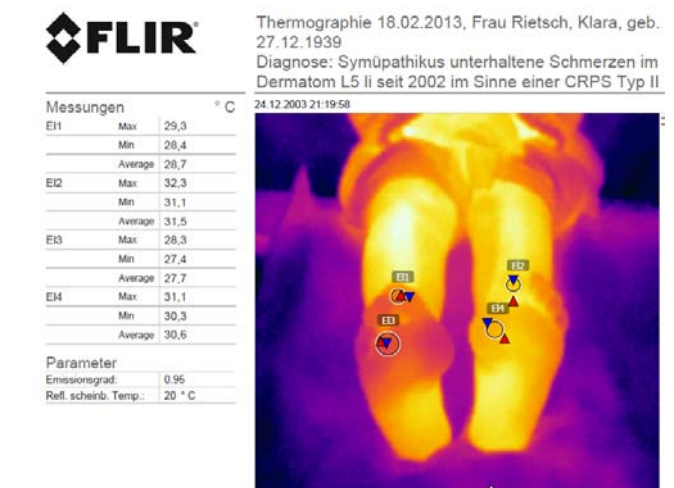
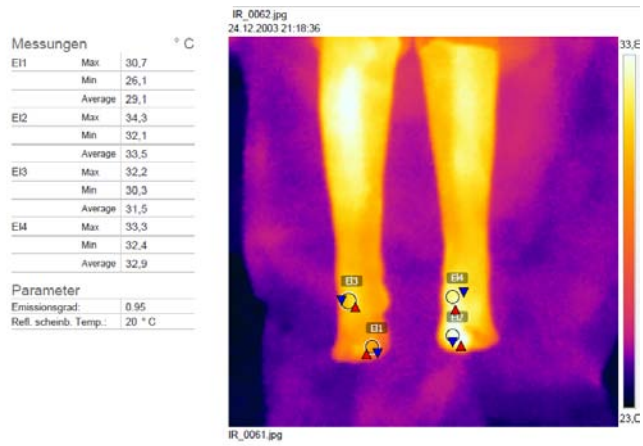


## CASE PRESENTATION:

The patient is a 73 year old lady who has been treated for pain in the lower back in a hospital in Freiburg. She has had several operations on the spine for spinal canal stenosis before.

In an invasive therapy, 5 hours after CT guided L5 periradicular therapy, a severe pain appears in the left first toe and a small part of the left dorsum of the foot; after that, no medication has been effective. Sometimes, the left first toe is swollen; and the temperature quite varies from time to time (sometimes very warm, sometimes very cold). Thermography shows these changes. The first toe and the left forefoot are very tender even to shoe, socks, and coverlet while sleeping.





Diagnosis: CRPS Type II L5

Proposed treatments: Anti-neuropathic drug  $\implies$  PRT L5  $\implies$  Sympathetic ganglion block  $\implies$  SCS